



# Coccyx-Neck - Romania

I am Dr. Narcisa Marcu, specializing in radiology and I work at Providenta Hospital in Iasi. I am also a Bowen practitioner.

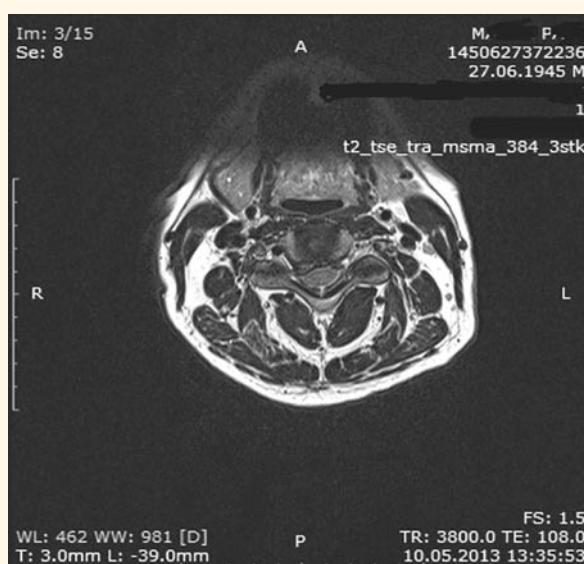
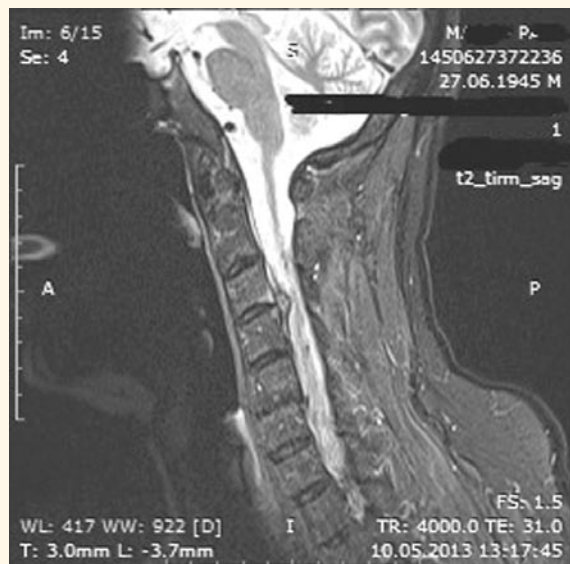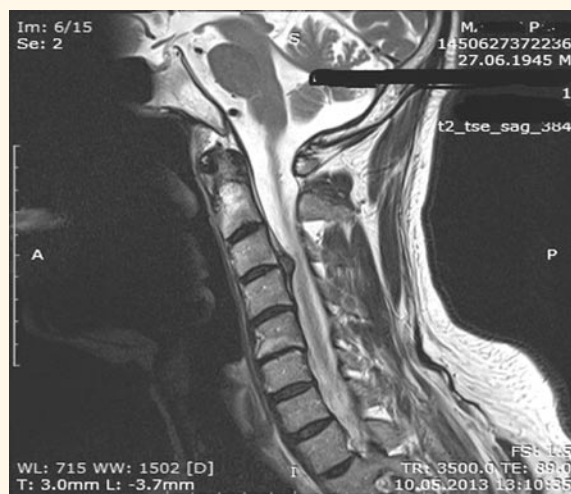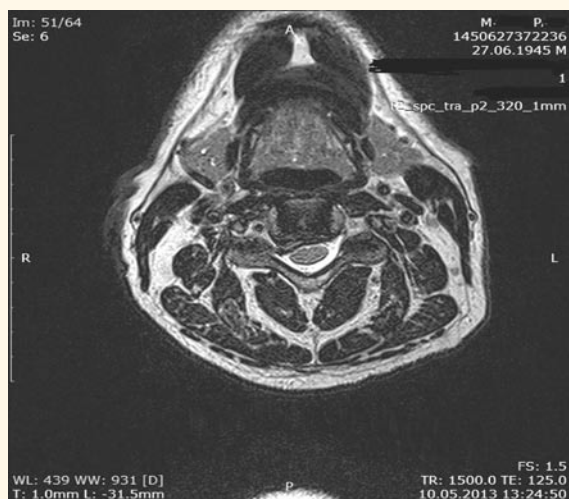I had a male patient, 68 years old, referred to the Imagistic Department, with torticollis on the right side, severe pain at cervical level irradiating down the shoulder and right arm, tingling and numbness in the fingers, muscular spasms in the cervical region, and functional restrictions of lateral movement and rotation of the cervical spine.

The patient couldn't be examined by MRI because he couldn't stay still for 30 minutes, due to the intense pain and constant spasms.

I suggested he start the Bowen treatments to relieve the symptoms and after the first four sessions, the pain was 50% less intense and the spasms disappeared completely, so the patient could have an MRI done (on the 10.05.2013) which showed:

- the rectitude of the cervical spine (no normal curvature)
- a disc sub-ligamentar hernia C3-C4, par median right, that determines a Dural sac compression and a radicular compression, intraradicular, on the C4 root on the right.
- degenerative alterations of the discs at levels C2-C3, C3-C4, C4-C5, C5-C6, associated with space clamping and Modic 1 alterations at C5-C6 level.

## MRI Examination from 10.05.2013



The patient was recommended by a rheumatologist to follow a kinesiology program of ten sessions, under specialised supervision. He continued at home to perform the specific exercises, every day for the next two to three months and once a week afterwards.

I decided to continue with Bowen Therapy sessions, since there was no incompatibility between kinesiology and Bowen, so I gave him another eight sessions, every seven days.

The pain and the functional restriction were 90% gone after the twelfth session and I decided together with the patient to take a break.

For one month he was feeling good but then the pain was reappearing at the cervical level, so I kept treating him with one or two sessions per month, for the following seven months.

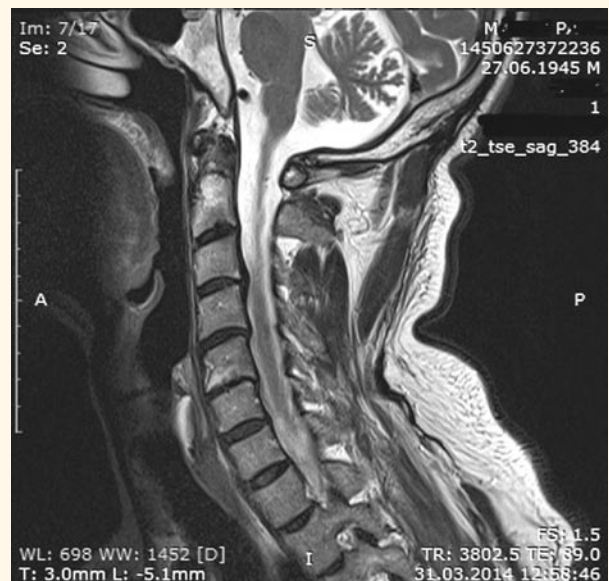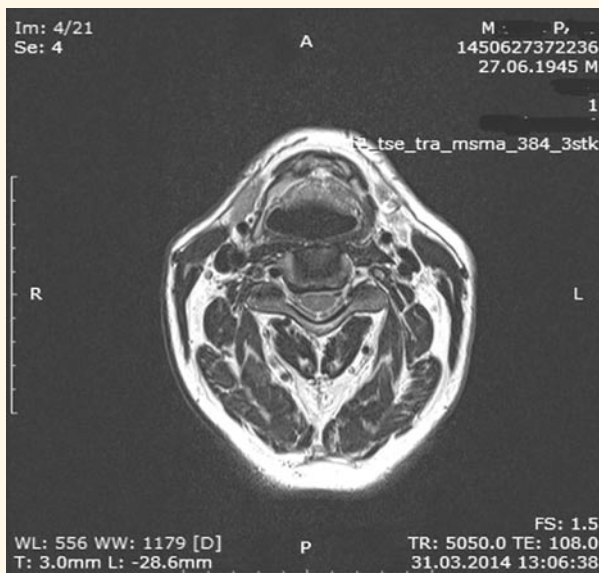
At the 19th session I applied the **Coccyx-Neck** procedure.

For three days after the treatment the patient reported the pain increased, describing the sensation like somebody was trying to re-arrange his spine. In the fourth day the pain was completely gone and there were no more restrictions of movements either. The patient requested to have another MRI done, being convinced he was completely healed.

The MRI examination from the 31.03.2015 revealed:

- the complete disappearance of the migrated disc fragment, sub-ligamentar, paramedian right at the C3-C4
- the presence of a thickened, fibrosis like, longitudinal, posterior ligament, grown on top of the former lesion
- reappearance of the normal cervical curve.

### MRI Examination from 31.03.2014



I have to admit I have never seen such a spectacular result!

The patient “inner doctor” found the best way to solve the problem, by “securing” the area and eliminating all risks and functional limitations! ***The Bowen technique is amazing!***

*DR. NARCISA MARCU*  
Iasi – Romania